



Curing Sleep apnea for ever

THE LIFE CHANGING NEW TREATMENT

Clinical Paper: Bimaxillary „rotation advancement“
procedures in patients with obstructive sleep apnea:
a 3-dimensional airway analysis of morphological changes.

M.J. Zinser, S. Zachow, H.F. Sailer

CURING SLEEP APNEA FOR EVER

Major Symptoms and consequences associated with obstructive sleep apnea

A widespread disease

Sleep apnea is a widespread disease affecting an enormously large segment of the population. Unlike frequently thought, it can be cured.

The source of the problem

Sleep apnea stems from growth disturbance of the jaws leading to insufficient pertinent air-intake. Prof. Sailer's unique technique cures this in a lasting fashion.

Many symptoms – now curable

Untreated sleep apnea leads to a long list of symptoms:• Snoring

- Breathing stops (apnea)
- Daytime Fatigue
- Physical inactivity
- Concentration problems
- Sudden sleep (cardriving, television etc.)
- Oxygen desaturation in blood
- Drop in intellectual and physical performance
- Impotence
- Reduced life expectancy
- Hypertension (high blood pressure)
- Stroke
- Heart attack
- Prone to respiratory infections
- Creeping dementia
- Depression and psychological challenges

Conclusive Scientific evidence

The new study by Mr. Zinser, S. Zachow and H.F. Sailer attached provides conclusive scientific evidence on the airway widening effects of Prof. Sailer's operational technique «Roation Advancement» of the upper and lower jaw.



*Professor Hermann F. Sailer
Dr. med., Dr. med. dent.,
Dr. h.c. mult., Dr. sc. h.c.,
FDSRCS (Engl.), FRCS (Edinb.)*



Bimaxillary 'rotation advancement' procedures in patients with obstructive sleep apnea: a 3-dimensional airway analysis of morphological changes

M. J. Zinser^a, S. Zachow^b,
H. F. Sailer^c

^aDepartment of Craniomaxillofacial and Plastic Surgery, University Cologne, Germany; ^bDivision Scientific Computing, Department Visualization and Data Analysis, ZUSE Institut, Berlin-Dahlem, Germany; ^cClinic Professor Sailer, Toblerstrasse 51, Zürich, Switzerland

M. J. Zinser, S. Zachow, H. F. Sailer: Bimaxillary 'rotation advancement' procedures in patients with obstructive sleep apnea: a 3-dimensional airway analysis of morphological changes. *Int. J. Oral Maxillofac. Surg.* 2012; xxx: xxx-xxx. © 2012 International Association of Oral and Maxillofacial Surgeons. Published by Elsevier Ltd. All rights reserved.

Abstract. The aim of this retrospective three dimensional (3D) computed tomographic analysis was to investigate the morphological airway changes in 17 obstructive sleep apnea (OSA) patients following bimaxillary rotation advancement procedures. Morphological changes of the nasal cavity and naso-, oro- and hypopharynx were analysed separately, as were the total airway changes using nine parameters of airway size and four of shape. The Wilcoxon test was used to compare airway changes and the intraclass correlation coefficient to qualify inter-observer reliability. Following bimaxillary advancement and anti-clockwise maxillary rotation, the total airway volume and the lateral dimension of the cross-sectional airway increased significantly. The total length of the airway became shorter ($p < 0.05$). Remarkable changes were seen in the oropharynx: the length, volume, cross-sectional area (CSA), antero-posterior and medio-lateral distance changed ($p < 0.05$). This combined with a significant 3D change in the shape of the airway from round to elliptical. The average cross-sectional oropharyngeal area was nearly doubled, the minimal CSA increased 40%, and the hyoid bone was located more anterior and superior. Inter-examiner reliabilities were high (0.89). 3D airway analysis aids the understanding of postoperative pathophysiological changes in OSA patients. The airway became shorter, more voluminous, medio-laterally wider, and more compact and elliptical.

Key words: orthognathic surgery; rotation advancement; bimaxillary surgery; obstructive sleep apnea; 3D analysis; airway.

Accepted for publication 1 August 2012

Obstructive sleep apnea (OSA) is a disorder characterized by temporary cessation of breathing (apnea) or shallow breathing (hypopnea).¹ The signs and symptoms are repeated apneic and hypopneic episodes during sleep, excessive daytime sleepiness, night sweats, confusion, headaches and reduced attention span. Recent studies have suggested an association between OSA and certain cardiovascular sequelae, such as hypertension and coronary artery disease.²

The primary goal of a surgical approach to severe cases of OSA is to resolve or significantly improve the clinical situation, thus avoiding the use of nasal-continuous positive airway pressure (N-CPAP), which is frequently badly tolerated or refused. Empirical studies have suggested that rates for CPAP use range from 30 to 60%.²⁻⁴ Surgical techniques involving the soft tissues, such as uvulopalatopharyngoplasty,⁵ hyoid suspension, partial glossectomy⁶ and lingual suspension have given partial but not long-lasting results.

Therefore orthognathic procedures have gained ground. Initially, mandibular advancement⁷ alone and more recently, bimaxillary maxillo-mandibular advancement (MMA)⁸⁻¹⁰ and rotation advancement (RA) procedures¹¹⁻¹⁴ have been employed. With MMA, all the soft-tissue structures making up the pharyngeal walls are tightened at once; this stops them from

collapsing, or reduces this occurrence, by acting on the suprahyoid and palatal muscles and on the lateral musculature of the pharynx. The result is a significant increase in airway space and the resolution of the syndrome in a high (95%) percentage of cases, as well as improved quality of life.¹⁵ While 2D imaging, orthopantomograms and lateral cephalograms have traditionally served as the radiologic standard for airway assessment in OSA and cephalometric measurements are useful for analysing airway size in the sagittal plane, they do not depict the three-dimensional (3D) airway anatomy accurately. The most physiologically relevant information is obtained from axial images, perpendicular to the direction of airflow: the axial plane is not visualized on lateral cephalograms.⁸ 3D computed tomography (CT)-studies have been used to characterize the airway anatomy^{3,16-18} and the morphological changes in patients with OSA.¹⁸ A systematic evaluation of OSA patients compared to non-OSA controls, using normative 3D CT upper airway parameters, has been published recently.¹⁹ The results indicate that the presence of OSA is associated with an increase in airway length. Airways that were more elliptical in shape and mediolaterally oriented had a decreased tendency towards obstruction. Only a small number of 3D CT studies with a limited number of patients are available evaluating the

morphological changes of the airway in OSA using patients treated with orthognathic surgery procedures.^{18,19} The authors hypothesize that 3D CT analysis of airway size and shape in patients with OSA will provide reliable and clinically useful information to supplement or finally replace that provided by 2D cephalograms.

The purpose of the present study was to investigate the 3D morphological and pathophysiological airway changes in OSA patients following the bimaxillary rotation advancement procedure.

Materials and methods

This is a retrospective study of 17 patients (10 male and 7 female) with OSA who were treated by the third author (HFS). Patients included in this study had severe clinical OSA symptoms, and the diagnosis was confirmed by overnight polysomnogram findings. 11 patients had previously undergone other surgery, such as uvuloplasties, septoplasties, tonsillectomies and adenotomies (Table 1), at different institutions with no long-lasting effect. All patients had been undergoing treatment with N-CPAP for some time but had not tolerated it well.

The bimaxillary RA procedure was performed in all patients to create harmonic antefacial physiognomies (Figs. 1 and 2). This technique¹²⁻¹⁵ represents a further

Table 1. Demographic and functional polysomnogram data for the patients and rotation advancement of the mandible.

No.	Age (years)	Gender	Height (cm)	Surgical history	Polysomnogram		Rotation advancement (mm)		Adjunctive surgeries
					Pre-AHI/h	Post-AHI/h	Mandible antero-posteriorly	Maxilla counter-clockwise	
1	56	M	180	UP, SP, TA	60	6	9.0	3.5	G, RT
2	63	M	170	UP	65	9	12.0	4.5	G, SP
3	45	M	175	SP, T	74	13	13.0	5	RT
4	29	F	190	TA, UP	36	4	11.0	3.5	G, SP
5	51	M	177	UP, TA	40	3	15.0	4	G, SP, RT
6	48	F	156	UP	50	10	10.0	4	SP, RT
7	42	M	164	None	55	9	10.5	3.5	G, RT
8	37	M	170	None	60	4	10.4	3	G, RT
9	40	F	175	None	26	3	10.2	5	SP
10	33	M	178	UP, T	45	9	12.8	4	G, RT
11	35	M	180	TA	30	5	9.7	3.4	G, RT
12	32	F	164	None	33	3	9.1	4.3	G, SP
13	28	M	190	SP	27	7	12.0	5	None
14	25	F	170	UP, T	39	11	10.5	4.4	G, SP
15	30	F	171	None	40	8	10.4	4.1	G, RT
16	32	F	172	UP, TA	70	7	10.6	4	G, SP, RT
17	31	M	174	None	65	10	10.0	3	G, RT
Mean	38.64 ± 10.75		173.9 ± 8.64		47.94 ± 15.64	5.64 ± 2.09	11.84 ± 1.82	4.10 ± 0.60	
Min	25		156		26	2	9	3	
Max	63		190		74	12	15	5	

M, male; F, female; UP, uvulopalatopharyngoplasty; SP, septoplasty; T, tonsillectomy; TA, tonsillectomy and adenoidectomy; G, genioplasty; RT, reduction of the inferior turbinate.

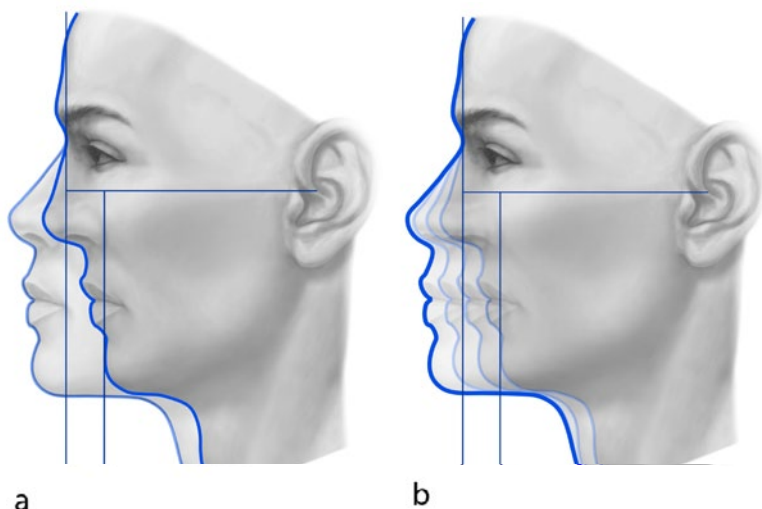


Fig. 1. (a) The typical facial backward type physiognomies of OSA patients and (b) an antifacial profile.

modification of the MMA procedure. Following a Le Fort I osteotomy and a long sagittal splitting of the mandible, the maxilla was advanced forward and mainly rotated anti-clockwise to create a new inclination angle of the occlusional and maxillary plane. The mean antero-posterior advancement of the mandible was 11.84 ± 1.82 mm, measured perpendicular to the sagittal plane, and the mean anti-clockwise rotation of the maxilla was 4.13 ± 1.01 mm, creating a gap in the posterior part of the zygomatic buttress (Table 1 and Fig. 3). The anterior advancement of the maxilla was 2.1 ± 0.53 mm measured parallel to the maxillary plane. The maxilla was fixed

with two to three plates (2.0) on each side.

Following the new anti-clockwise rotated occlusional plane, the mandible could be positioned farther anteriorly, as opposed to the conventional MMA procedure, where the maxilla would be positioned too far forward (>10 mm),^{3,18,20} thus decreasing the nasolabial angle too much and resulting in an unnatural appearance.

The mandible was fixed with 2–4 bicortical screws on each side. In 13 patients an associated genioplasty was performed, following the technique described by Trauner and Obwegeser.²¹ Additional septoplasty was carried out in 8 patients and a reduction of the inferior turbinates in 11

patients (Table 1). Maxillo-mandibular fixation was not necessary but patients used maxillo-mandibular bands for 3–4 weeks. Approximately 3–4 months after the RA procedure, all patients underwent an overnight polysomnogram study.

Image acquisition and analysis

Helical maxillofacial noncontrast CT scans (Evolution 6, Siemens, Munich, Germany) consisting of 2.5 mm axial tomograms, with reconstructions in the axial, coronal and sagittal planes, were used. The patients were in the supine position and were instructed to remain still, to not swallow, to place the tongue against the incisor teeth and to hold their breath at the end of exhalation. The mandible was positioned centrally and the lips were relaxed. A reference line of 50 mm was used to calibrate the measurements for each image. Postoperative scans were completed 3–6 months following RA.

The scans were imported into the analysing software ZIB-Amira[®] (Zuse Institute Berlin). Digital 3D model reconstructions of the airways were made using a semiautomatic region growing method with a fixed Hounsfield threshold value (Figs. 3–5). The superior upper airway boundary was defined at the level of the ethmoid cells and the inferior boundary 2 cm below the base of the epiglottis, consistent with methods described in previous studies.¹⁷ A reliable coordinate system consisting of the Frankfort horizontal plane or basal skull plane (BSP) and a median plane was set up (Fig. 4). The boundaries of the compartments were defined parallel through the BSP, indicating the nasal cavity (compartment A) intersected inferior with the posterior nasal spine, the nasopharyngeal compartment (B) with the tip of the uvula as its inferior boundary, the oropharyngeal compartment (C) intersected inferior with the tip of the epiglottis and the hypopharyngeal compartment (D) with its inferior border 2 cm below the base of the epiglottis (Figs. 4 and 5).

Airway parameters

Once the 3D digital models were constructed, the airway was systematically analysed using metric, 2D and 3D parameters. The following airway parameters (Tables 2 and 3) were used to analyse the anatomical compartments of the airway: volume (VOL), surface area (SA), length (L), CSA, antero-posterior dimension (AP), and medio-lateral dimension (LAT). The LAT/AP ratio and sphericity

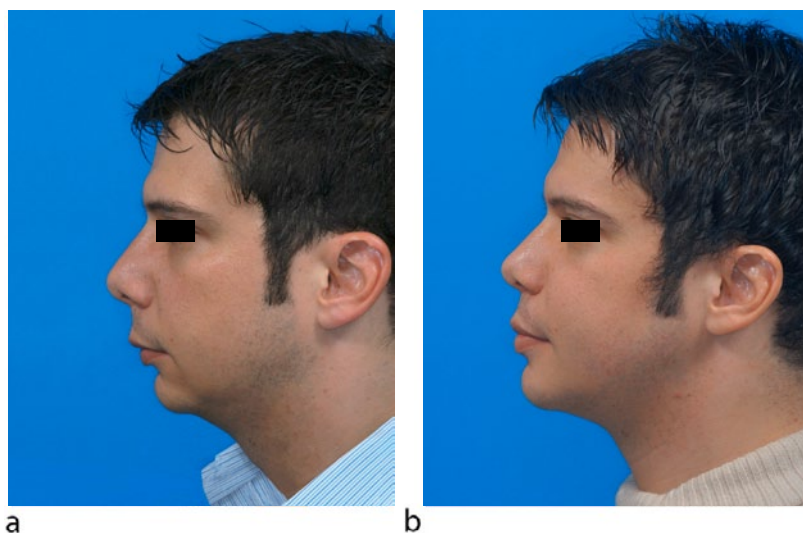


Fig. 2. (a) Preoperative profile of an OSA patient, showing a backward physiognomy and (b) postoperatively, a harmonic antifacial physiognomy could be achieved following RA surgery.

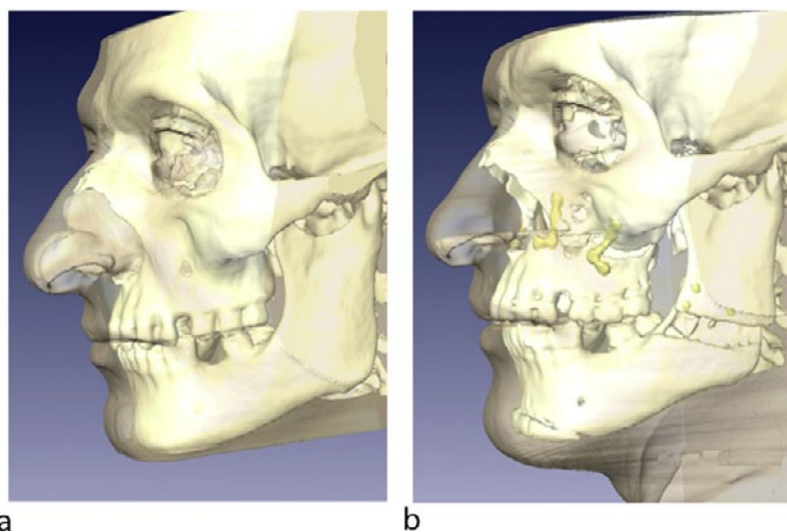


Fig. 3. Superimposed volumetric representation of the skeleton and the soft tissue. (a) Preoperative and (b) postoperative view following RA surgery.

describes the 3D shape of the airway. The metric and morphological changes of the position of the hyoidal bone following RA surgery were described, measuring the distance of the hyoidal bone to the BSP (L hyo), as well as the distance between the hyoidal bone and the mandible (L mh) and the angle between the hyoid and the mandible (Figs. 5 and 6). All parameters were measured in a reproducible way according to the BSP (Fig. 4). To determine inter-observer variability, a second operator performed the analysis in 7 randomly selected patients in the study group, independent of the first operator.

Statistical analysis

All data were analysed using SPSS for Windows Vista (version 17.0; SPSS, Inc., Chicago, USA). Inter-observer reliability was qualified with use of Pearson's intraclass correlation coefficient. Descriptive statistics were calculated for all variables (Tables 2 and 3). A Wilcoxon test of paired samples was used to calculate the pre- and postoperative morphological changes of various parameters of the airway. The mean values are displayed in Tables 2 and 3. The changes in the airway parameters were expressed as percentages compared to the preoperative values. A value of $p < 0.05$

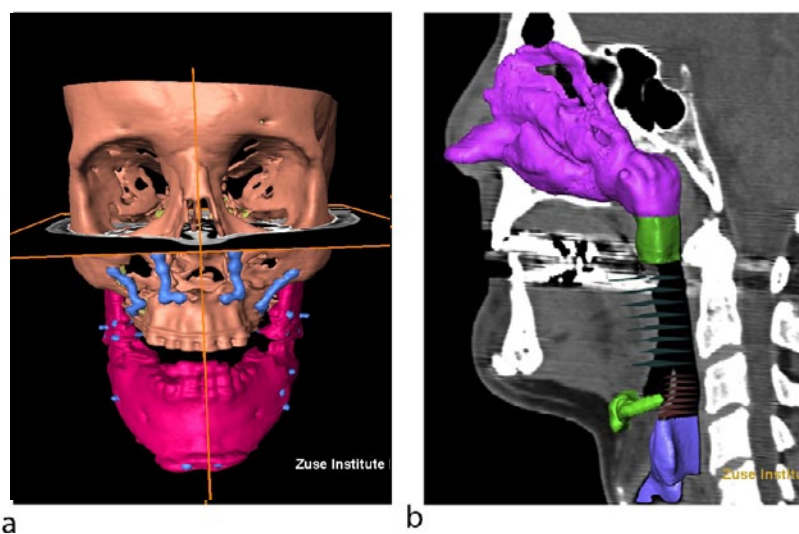


Fig. 4. The screen capture displays the 3D-view of the skull, including a coordinate system (a) consisting of the BSP and median plane. The screen capture on the right (b) illustrates the segmentation of the airway, including the setup of axial planes systematically parallel to the BSP.

was considered to be statistically significant (Table 3).

Results

Demographic, anthropometric, clinical and surgical data for the patient population are summarized in Table 1. The patients' age range was 25–63 years (mean 38.64 ± 10.75 years). Their height ranged from 156 to 190 cm (mean 173.9 ± 8.64 cm). All patients showed a significant functional and clinical improvement as well as a significant improvement of the apnea–hypopnea index (AHI). The preoperative values were in the range 26–74/h (mean 47.94 ± 15.64 /h); postoperatively the AHI was significantly reduced, representing nearly normal values within the range 3–13/h (mean 5.64 ± 2.09 /h, $p < 0.05$). From day 1 post-surgery, the use of the N-CPAP mask was no longer necessary for all patients.

Morphological airway changes

Inter-observer reliability of the airway analysis was excellent ($0.89–1$, $p < 0.05$). The focus of this study was to evaluate morphological airway changes following bimaxillary rotation advancement. The mean values are summarized in Table 3. Postoperatively there was a significant increase of the airway space in all compartments of the airway. The total airway space increased significantly, about 45% (pre-surgical 49.74 ± 2.66 ml; post-surgical 72.28 ± 3.50 ml; $p < 0.005$). The highest increase of the airway space, 56.29% (mean 31.07 ± 1.77 ml to 48.56 ± 2.33 ml, $p < 0.005$), was seen in the nasal cavity (Fig. 5). Similar changes were observed for the SA (cm^2) of the airway (Table 3). The total SA of compartments A–C changed significantly ($p < 0.05$), although the SA of the hypopharyngeal compartment (D) did not change significantly ($p < 0.074$). Interesting postoperative changes revealed the length of the airway according to the BSP. The RA procedure shortened the total length of the airway about 16.87% ($p < 0.005$). The nasopharyngeal compartment (B) was lengthened about 11.35% ($p < 0.005$). The oropharyngeal compartment (C) was shortened about 28.52% ($p < 0.005$). The hypopharyngeal compartment (D) was shortened about 6.88% ($p < 0.008$). The analysis of the CSA of the airway was measured in the axial planes parallel to the BSP. The CSA of the oropharyngeal compartment (C) was significantly enlarged postoperatively (about 92.9%), and in the hypopharyngeal

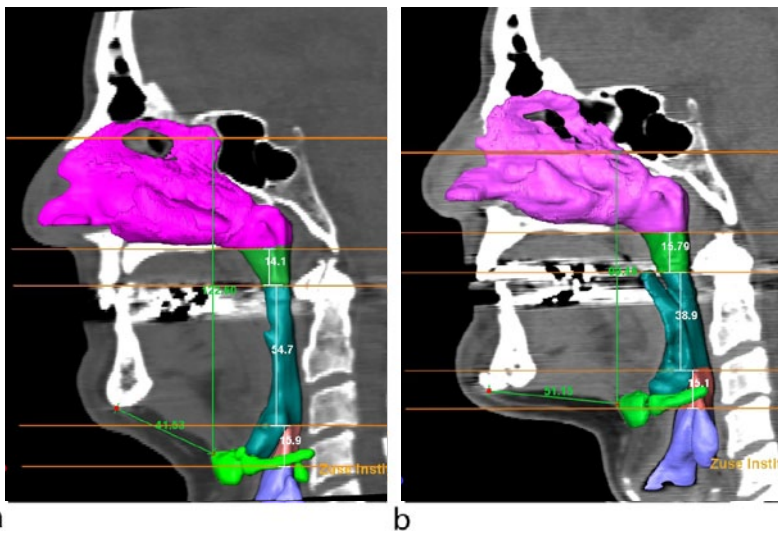


Fig. 5. (a) Pre- and (b) postoperative screen capture displaying the sagittal view. The whole airway including the anatomical compartments (nasal cavity, nasopharynx, oropharynx and hypopharynx) was segmented and visualized. The lengths of the airway including all compartments, including the position of the hyoid bone, were measured according to the BSP. The screen capture (b) following rotation advancement surgery clearly illustrates the shortening of the airway and the change in shape, including the cranial positioning of the hyoid bone.

compartment (D) an increase of about 40.35% could be seen. The minimal CSA (min CSA) of the entire airway increased postoperatively about 38.61% ($p < 0.005$), the maximal cross-sectional (max CSA) area increased about 12.33% ($p < 0.005$), and the average cross-sectional (avg CSA) area enlarged about 50.29% ($p < 0.005$) (Fig. 6). The metric analysis of the LATs in the axial planes of the airway also showed significant changes following RA surgery. Postoperatively, the mean

values of the medio-lateral distance in the oropharyngeal compartment of the airway (C) increased about 66.38%, in the nasopharyngeal compartment (B) about 12.5%, and in the hypopharyngeal compartment (D) about 12.2%. The average medio-lateral distance (LAT) of the airway increased about 24% ($p < 0.005$), the minimal cross-sectional distance of the airway increased about 13.1% ($p < 0.005$), and the mean values of the widest medio-lateral distance (LAT max) were reduced about 36.7%

($p < 0.005$) (Fig. 6). The AP distance showed no significant changes in the naso- and hypopharyngeal compartments (B and D $p < 0.058$). The mean values of the oropharynx (C) increased in length about 33.6% ($p < 0.005$), the minimal AP (min AP) enlarged about 28.57% ($p < 0.009$), and the maximal AP (max AP) of the airway measured in the axial planes doubled (107%, $p < 0.005$). The average antero-posterior distance (avg AP) of the whole airway enlarged about 12.5% ($p < 0.008$) following rotation advancement surgery.

Shape of the airway

The metrical ratio of the LAT/AP distance describes the geometrical changes of the shape of the airway following RA surgery (Fig. 6). The mean values of the LAT/AP ratios showed significant changes in all compartments. The LAT/AP ratios increased in the nasopharyngeal (mean 1.09 ± 0.06 – 1.21 ± 0.02 ; $p < 0.05$), oropharyngeal (mean 1.68 ± 0.03 – 1.91 ± 0.02 ; $p < 0.08$) and hypopharyngeal (mean 2.02 ± 0.15 – 2.30 ± 0.29 ; $p < 0.016$) compartments. This indicates a significant geometric change of the shape of the airway from round to more elliptical, due to a more medio-lateral than antero-posterior widening of the airway in the axial plane following the RA procedure (Fig. 6). Comparable changes could be observed for the minimal LAT/AP, average LAT/AP and maximal LAT/AP ratios. The sphericity describes the compactness of the 3D shape of the airway. Following RA surgery, the 3D shape of the airway became more spherical and compact in all compartments ($p < 0.05$), indicating a reduced probability of collapse (Tables 2 and 3).

Position of the hyoid bone

The RA procedure changed the anatomical position of the hyoid in such a way that the position of the hyoid bone (L hyo) was postoperatively positioned on average 2.56 cm more cranially (12.12 ± 1.09 cm versus 9.56 ± 0.71 cm; $p < 0.005$) in relation to the skull base (Fig. 5). The distance from the genial tubercle of the mandible to the hyoid (L mh) was enlarged about 21.43% (4.2 ± 0.15 cm– 5.10 ± 0.08 cm; $p < 0.005$). The mean mandibulo-hyoid angle was diminished about 27.3° (pre-surgical $42.6^\circ \pm 2.06^\circ$ to post-surgical $15.3^\circ \pm 1.49^\circ$; $p < 0.005$).

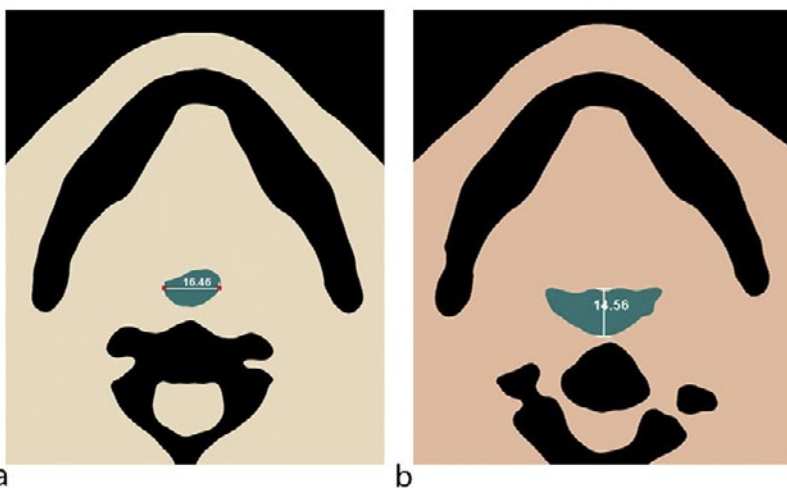


Fig. 6. Screen capture representing the cross-sectional axial views of the preoperative (a) and postoperative (b) airway shape. Following rotation advancement surgery, the cross-sectional area of the airway enlarged more medio-laterally than antero-posteriorly, concluding a form change of the airway from round to more elliptical.

Table 2. Definition of anatomical compartments and airway parameters.

Airway compartments	Symbol	Definition		
Nasal cavity	A	From ethmoid cells to posterior nasal spine		
Nasopharynx	B	From posterior nasal spine to tip of the uvula		
Oropharynx	C	From tip of uvula to tip of epiglottis		
Hypopharynx	D	From tip of epiglottis to 2 cm below the base of the epiglottis		
Airway parameter	Symbol	Type	Unit	Definition
Length and size of the airway				
Airway space				
Total	VOL	3D	ml	Airway space
Nasal cavity	VOL A			
Nasopharynx	VOL B			
Oropharynx	VOL C			
Hypopharynx	VOL D			
Surface area	SA		cm ²	Surface area of airway
Total	SA tot	2D		
Nasal cavity	SA A			
Nasopharynx	SA B			
Oropharynx	SA C			
Hypopharynx	SA D			
Length	L	1D	mm	Length of the airway, measured perpendicular to the basal skull plane (BSP)
Total	L tot			
Nasal cavity	L A			
Nasopharynx	L B			
Oropharynx	L C			
Hypopharynx	L D			
Cross-sectional area	CSA	2D	mm ²	Cross sectional area of the airway, measured parallel to the basal skull plane
Nasopharynx	CSA B			
Oropharynx	CSA C			
Hypopharynx	CSA D			
Minimum	min CSA			
Maximum	max CSA			
Average	avg CSA			
Medio-lateral distance	LAT	1D	mm	Medio-lateral distance of the cross sections of the airways, measured in the axial planes parallel to the basal skull plane
Minimum	LAT B			
Maximum	LAT C			
Average	avg LAT			
Antero-posterior dimension	AP	1D	mm	Antero-posterior distance of the cross sections of the airways, measured in the axial planes parallel to the basal skull plane
Nasopharynx	AP B			
Oropharynx	AP C			
Hypopharynx	AP D			
Minimum	AP min			
Maximum	AP max			
Average	avg AP			
Shape of the airway				
LAT/AP ratio	LAT/AP	Ratio	–	Ratios of the medio-lateral and antero-posterior distances, indicating the geometrical shape of the cross-sectional area of the airway in 2D
Nasopharynx	LAT/AP B			
Oropharynx	LAT/AP C			
Hypopharynx	LAT/AP D			
Minimum	LAT/AP min			
Maximum	LAT/AP max			
Average	LAT/AP avg			
Sphericity (Ψ)/compactness	Ψ	Formula	–	Mathematical measure of the sphericity (Ψ) or compactness (Ψ) = $[\pi/3(6 \times \text{VOL})^{2/3}]/\text{SA}$ Indicating the 3D shape of the airway, a flat and less compact object has a Ψ of 0 and a sphere and compact object a Ψ of 1
Total	Ψ tot			
Nasopharynx	Ψ A			
Oropharynx	Ψ B			
Hypopharynx	Ψ C			
Position of the hyoid bone				
Distance of the mandible to hyoid bone	L mh	1D	mm	Distance of the genial tubercle of the mandible to the hyoid bone
Mandible–hyoid angle	α			Angle between the genial tubercle of the mandible and the hyoid bone
Length of the hyoid to the skull base	L hyo			Length of the hyoid bone to basal skull plane



Table 3. Mean values of the airway parameters.

Airway parameter	Preoperative						Postoperative						Operative changes (%)	Sig.
	Min Stat	Max Stat	Mean		SD Stat	Var Stat	Min Stat	Max Stat	Mean		SD Stat	Var Stat		
			Stat	SE					Stat	SE				
Size of the airway														
Airway space														
VOL tot	46.40	55.60	49.74	.84	2.66	7.11	67.40	77.50	72.28	1.10	3.50	12.26	45.32	.005
VOL A	28.00	33.20	31.07	.56	1.77	3.16	45.00	52.00	48.56	.73	2.33	5.44	56.29	.005
VOL B	3.30	3.80	3.55	.04	.15	.02	4.00	4.50	4.27	.046	.14	.02	20.28	.003
VOL C	12.00	13.30	12.51	.12	.39	.15	16.20	18.40	17.18	.22	.70	.49	37.33	.005
VOL D	1.90	2.20	2.07	.02	.09	.01	2.60	2.77	2.67	.01	.05	.01	28.99	.005
Surface area														
SA tot	26.00	26.60	26.25	.06	.20	.043	28.00	30.60	29.91	.22	.72	.52	13.94	.005
SA A	18.70	20.00	19.35	.10	.31	.10	20.80	22.00	21.52	.11	.34	.12	19.35	.005
SA B	1.35	1.47	1.42	.01	.04	.00	1.50	1.55	1.52	.01	.10	.00	7.04	.005
SA C	4.30	4.45	4.39	.01	.04	.01	5.55	5.75	5.65	.02	.06	.01	28.7	.005
SA D	1.06	1.90	1.17	.08	.25	.06	1.28	1.36	1.31	.01	.02	.00	11.97	.074
Length														
L tot	7.90	8.55	8.36	.05	.18	.03	6.77	7.08	6.95	.03	.10	.01	-16.87	.005
L B	1.37	1.45	1.41	.01	.03	.01	1.50	1.66	1.57	.01	.04	.00	11.35	.005
L C	5.20	5.50	5.40	.02	.09	.01	3.80	3.95	3.86	.01	.04	.00	-28.52	.005
L D	1.55	1.65	1.60	.01	.03	.00	1.40	1.55	1.49	.02	.05	.00	-6.88	.008
Cross sectional area														
CSA B	2.10	3.50	2.42	.14	.45	.20	2.50	2.75	2.61	.02	.07	.01	8.75	.221
CSA C	1.80	1.90	1.83	.01	.03	.00	3.35	3.61	3.53	.02	.07	.01	92.9	.005
CSA D	1.09	1.20	1.14	.01	.04	.00	1.20	1.78	1.60	.06	.19	.03	40.35	.005
min CSA	.88	1.20	1.01	.04	.12	.01	1.30	1.70	1.40	.04	.13	.01	38.61	.005
max CSA	3.68	3.85	3.73	.01	.05	.00	4.16	4.25	4.19	.01	.02	.00	12.33	.005
avg CSA	1.72	1.79	1.75	.01	.02	.00	2.59	2.66	2.63	.01	.02	.00	50.29	.005
Medio-lateral distance														
LAT B	1.73	1.80	1.76	.01	.02	.00	1.80	2.20	1.98	.03	.11	.01	12.5	.005
LAT C	2.30	2.36	2.32	.01	.02	.00	3.60	4.10	3.86	.05	.14	.02	66.38	.005
LAT D	1.80	2.10	1.98	.03	.10	.01	2.20	2.50	2.42	.03	.09	.01	12.22	.005
LAT min	1.60	1.80	1.68	.01	.05	.00	1.83	2.00	1.90	.02	.05	.00	13.1	.005
LAT max	2.89	3.01	2.97	.01	.03	.00	1.80	2.10	1.88	.03	.08	.01	-36.7	.005
avg LAT	1.90	2.10	2.00	.02	.07	.01	2.30	2.59	2.48	.03	.09	.01	24	.005
Antero-posterior distance														
AP B	1.45	1.70	1.56	.02	.06	.00	1.59	1.70	1.63	.01	.04	.00	4.49	.058
AP C	1.20	1.31	1.25	.01	.03	.00	1.61	1.75	1.67	.01	.04	.00	33.6	.005
AP D	.80	1.30	1.01	.04	.14	.02	.99	1.30	1.13	.03	.09	.01	11.88	.058
AP min	.71	.84	.77	.01	.04	.00	.80	1.20	.99	.04	.13	.02	28.57	.009
AP max	1.75	1.90	1.85	.01	.04	.00	3.70	4.00	3.83	.03	.09	.01	107	.005
avg AP	1.19	1.40	1.28	.02	.08	.01	1.40	1.55	1.44	.02	.05	.00	12.5	.008
Shape of the airway														
LAT/AP ratio														
LAT/AP B	1.01	1.20	1.09	.02	.06	.00	1.18	1.25	1.21	.01	.02	.00	11.01	.005
LAT/AP C	1.65	1.75	1.68	.01	.03	.00	1.80	2.10	1.91	.03	.08	.01	13.69	.005
LAT/AP D	1.80	2.30	2.02	.04	.15	.02	2.00	2.80	2.30	.09	.29	.08	13.86	.016
LAT/AP min	2.10	2.25	2.16	.01	.04	.00	1.90	2.08	1.99	.01	.06	.00	-7.87	.005
LAT/AP max	1.57	1.61	1.59	.00	.013	.00	1.75	1.95	1.81	.01	.06	.00	13.84	.005
avg LAT/AP	1.40	1.65	1.51	.02	.09	.01	1.69	1.85	1.78	.01	.06	.00	17.88	.005
Sphericity														
Ψ tot	.62	.70	.65	.01	.02	.00	.70	.98	.87	.02	.07	.01	33.85	.008
Ψ B	.70	1.20	.90	.05	.15	.02	.95	1.30	1.08	.03	.11	.01	20	.028
Ψ C	.93	1.00	.95	.01	.01	.00	.94	1.20	1.02	.02	.08	.01	7.37	.005
Ψ D	.60	.67	.64	.01	.02	.00	.70	.85	.76	.01	.04	.00	18.75	.005
Position of the hyoidal bone														
L mh	4.00	4.50	4.20	.04	.15	.02	4.90	5.20	5.10	.02	.08	.01	21.43	.005
α	39.00	45.00	42.60	.65	2.06	4.26	13.00	18.00	15.30	.47	1.49	2.23	-64.08	.005
L hyo	10.50	14.00	12.12	.34	1.09	1.20	8.00	10.50	9.56	.22	.71	.51	-21.04	.005

SD, standard deviation; Var, variance; Stat, statistic; SE, standard error; Sig, significance, 2-tailed.

RA procedure

The RA procedure represents a surgical modification of the MMA technique. The essential aspect of the RA technique is that the maxilla was rotated mainly anti-clockwise and the mandible could be positioned on average up to 11.84 mm (± 1.82) more anterior. The rotation advancement of the jaws leads to a traction and antero-cranial positioning of the hyoid bone. The geometrical shape of the oropharynx was changed from round to more elliptical (Figs. 5 and 6). Besides this pathophysiological important issue, the RA technique also incorporates the aesthetic aspects of the facial physiognomy (Figs. 1 and 2). The aesthetically important point is that the antero-posterior position of the maxilla stays more or less the same when the RA technique is used, in contrast to the MMA technique, where the maxilla has to be anteriorly repositioned up to 10 mm. It goes without saying, that a forward positioning of the maxilla can be done simultaneously, if there is a retromaxilism existing, using the rotation advancement procedure. The RA procedure enables changing the facial physiognomy from a backward to a harmonic anteface profile and offers important advantages over the conventional MMA technique (Figs. 1 and 2).

Discussion

Until recently, 2D lateral cephalograms were used to assess skeletal and airway anatomy changes following orthognathic surgery procedures. These images can only be used for linear and angular measurements. In contrast, the 3D CT imaging technique enables clinicians to make linear measurements and calculate CSAs of the airway in three planes of space: coronal, sagittal, and axial. The axial plane, which is not visualized on a lateral cephalogram, is the most physiologically relevant plane because it is perpendicular to the airflow.¹⁶

For OSA surgery to be successful, it is necessary to determine and understand the anatomical causes and physiopathological mechanisms underlying the syndrome. A number of different areas may be targeted, but it is now generally agreed that restriction of posterior airway space is the critical point for the pathogenesis of OSA, especially if a vertical restriction is present.⁵ Analysis of the literature reveals that an increase in posterior airway space after bimaxillary advancement is superior to other surgical techniques, such as antero-inferior

osteotomy of the mandible or hyoid bone or lingual suspension.⁵ Li et al.²² showed that the 'tightening' effect of bimaxillary procedures affects the lateral walls of the pharynx, which is comprised of the aponeuroses and muscles of the hypopharynx; it thus offers a stable and significant reduction in the collapsibility of the hypopharynx (Fig. 5). Fairburn et al.²³ demonstrated in a limited number of patients an enlargement of the posterior airway space by MMA surgery using helical CT scans and 3D evaluation. Using 3D geometrical reconstruction and computational fluid dynamic simulations, it is possible to predict the likely success of treatment and to predict the amount of surgical movement necessary to create an adequate airflow.¹⁸ In patients with known severe OSA, RA surgery is undoubtedly a significant option. Initially, the MMA procedure was recommended as an alternative treatment option when uvulopalatoplasties or septoplasties, considered as first choice surgeries, failed or when patients presented with an extreme retrognath cephalometric pattern of craniofacial anomalies.²⁰ This protocol was suggested by some authors,²⁴ while others²⁵ proposed MMA as the first treatment option.²⁶ More recently, Ronchi et al.¹⁹ concluded that MMA surgery should be considered as a treatment of the first choice, even in patients without skeletal anomalies. The MMA technique initially described was used for anterior positioning of the maxilla and mandible of approximately 10 mm. From an aesthetic point of view, this is critical and negatively influences the facial physiognomy and creates a hyperantefacial profile (Fig. 1), with a naso-labial angle that is too small following the maxilla positioned too far anteriorly. As an alternative to the above-mentioned shortcomings, the authors favour the RA technique described as the first stage procedure.

More information is needed concerning the pathophysiological airway changes following the bimaxillary RA procedure. This 3D airway analysis found a significant increase in the airway space, the SA of the airway and more prominent widening in the medio-lateral than in the AP combined with a shortening of the length of the airway. The 3D shape of the airway became more elliptical and compact following RA surgery.

To interpret these morphological changes, it is necessary to understand the proposed pathophysiological mechanism of airway collapse in OSA. Airway collapse occurs because of a decrease in

intra-airway pressure to less than that of the external pressure, in a collapsible segment of the airway. The factors that predispose a patient to airway collapse are those that decrease intraluminal pressures (obstruction), increase external pressure (obesity, sleeping position), or decrease the resistance to collapse offered by the walls of the pharynx (collapsibility).^{8,16} Obstruction leads to a decrease of the intra-airway pressure by providing resistance to flow. According to Poiseuille's law ($R = (8\pi \times L) / \pi \times r^4$), resistance (R) at the site of an obstruction is directly proportional to its length and inversely proportional to the radius. In the present study, the authors found reduced airway length postoperatively, suggesting a possible cause of reduced upper airway resistance. Following RA surgery, the CSA was significantly enlarged in all compartments of the airway. This could explain the reduction of airway resistance according to Poiseuille's law. It is notable that the biggest change in lengths was seen in the oropharyngeal compartment, where shortening of about 28.7% was found, whereas the nasopharyngeal compartment was lengthened about 11.35%. This could indicate that the oropharyngeal compartment might be the key area of interest from a pathophysiological standpoint.

The upper airway consists of a single conduit, therefore resistance is added in series (Poiseuille's law). This suggests that a small increase in the airway CSA can be magnified in a reduction of the airway length. Mild enlargement at multiple levels of the airway might result in a larger reduction of the total airway resistance for a shorter airway length (Fig. 5). Airway shape can also affect airway collapsibility. Abrahamson and others have demonstrated that greater LAT/AP ratios are associated with fewer obstructive events.¹⁸ This might reflect the decreased collapsibility of airways that are larger in the LAT than in the AP dimension (Fig. 6). Mayer et al.²⁷ demonstrated that patients with OSA had more circular airways, with a low LAT/AP ratio, than patients who snored without having OSA. In agreement with this hypothesis, the authors found a significant change of the airway towards an elliptical shape following RA surgery (Figs. 5 and 6). Fairburn et al.²³ examined the effects of MMA surgery on the LAT/AP ratios in patients with OSA and showed that both the LAT and AP distance increased. In the present study, the authors found a predominantly LAT rather than an AP enlargement of the airway, indicating a



form change of the airway to a more elliptical shape (Fig. 6). Li et al. reported a significantly smaller LAT distance in OSA patients, compared to the controls.²⁸ The postoperative enlargement of the LAT distance seems to have an important pathophysiological impact and might reduce the collapsibility of the airway, but there are many other external factors that might influence the airway collapsibility and OSA symptoms, such as obesity, medication, and sleeping position.¹⁶

Both logistical and statistical limitations were encountered in the present study. Even though the sample size was limited, statistical significance was observed for the study population. The present study will be continued, and more patients will be added to the sample. Another potential limitation was that the CT scans in the present study were carried out on patients who were awake. The anatomy and physiology of the airway during sleep are different from those in awake people.¹⁶ The positioning of the patient's head, swallowing, inhalation and expiration during the CT scan might influence the statistical evaluation of the airway (type 1, 2 error).

The goal of the present study was mainly to find useful anatomic and morphologic changes of the airway following RA surgery. Therefore, the authors used reliable airway parameters and analysed the complete airway, including the anatomical compartments.

In conclusion, the RA technique described is able to combine the functional and aesthetic demands of OSA patients. The postoperative morphological changes to the airway were significant and effective: It became shorter, more voluminous, compact, medio-laterally wider, and more elliptical in shape, with a reduced collapsibility that leads to a significant improvement of clinical OSA symptoms, combined with a significant AHI improvement. The facial physiognomies of the OSA patients improved aesthetically and changed from a typical backward type to a harmonic antefacial profile. Additional studies are required, incorporating more patients and correlating the morphological changes with the sleep-related functional data in a long-term follow-up study.

Competing interests

No conflict of interests are existing.

Funding

No sources of funding.

Ethical approval

Not required.

References

- Ryan CM, Bradley TD. Pathogenesis of obstructive sleep apnea. *J Appl Physiol* 2005;**99**:2440–50.
- Pepin JL, Krieger J, Rodenstein D, Cornette A, Sforza E, Delguste P, et al. Effective compliance during the first three months of continuous positive airways pressure. A European prospective study of 121 patients. *Am J Respir Crit Care Med* 1999;**160**:1124–9.
- Weaver TE, Sawyer AM. Adherence to continuous positive airway pressure treatment for obstructive sleep apnoea: implications for future interventions. *Indian J Med Res* 2010;**131**:245–58.
- Engleman HM, Martin SE, Douglas NJ. Compliance with CPAP therapy in patients with the sleep apnoea/hypopnoea syndrome. *Thorax* 1994;**49**:263–6.
- Fujita S, Conway W, Zorick F, Roth T. Surgical correction of anatomic abnormalities in obstructive sleep apnea syndrome: uvulopalatopharyngoplasty. *Otolaryngol Head Neck Surg* 1981;**89**:923–34.
- Straith RE, Ritter G. Partial resection of the tongue for the amelioration of obstructive sleep apnea. A report on 34 cases with long-term follow-up. *J Craniomaxillofac* 1997;**25**:305–9.
- Krekmanov L, Andersson L, Ringqvist M, Wilhelmsson B, Walker-Engstrom ML, Tegelberg A, et al. Anterior-inferior mandibular osteotomy in treatment of obstructive sleep apnea syndrome. *Int J Adult Orthod Orthognath Surg* 1998;**13**:289–97.
- Isono S, Morrison DL, Launois SH, Feroah TR, Whitelaw WA, Remmers JE. Static mechanics of the velopharynx of patients with obstructive sleep apnea. *J Appl Physiol* 1993;**75**:148–54.
- Riley RW, Powell NB, Guilleminault C. Obstructive sleep apnea: a surgical protocol for dynamic upper airway reconstruction. *J Oral Maxillofac Surg* 1993;**51**:742–7.
- Prinsell JR. Maxillomandibular advancement surgery in a site-specific treatment approach for obstructive sleep apnea in 50 consecutive patients. *Chest* 1999;**116**:1519–29.
- Haers PE, Sailer HF. Chirurgische Möglichkeiten bei obstruktiven nächtlichen Atmungsstörungen. *Med Mitteilungen der SUVA* 1994;**67**:18–24.
- Sailer HF, Zachow S, Zinser M. Treatment of obstructive sleep apnea with orthognathic rotation-advancement procedures. 3-D analysis of functional & anatomical airway changes. Presentation at the European Academy of Cranio-Maxillo-Facial Surgery in Bruges, Belgium, 14.–17.09. 2010. *J Craniomaxillofac Surg* 2010;**38**(Suppl. 1):2.
- Sailer HF. Beauty and success the prejudice is inside us. Presentation at the European Association of Cranio-Maxillo-Facial Surgery in Barcelona, Spain, 12.–16.09.2006. *J Craniomaxillofac Surg* 2006;**34**(Suppl 1):3.
- Sailer HF. Rotation advancement of the face, for a new dimension of attractiveness, the reverse face lift, and the treatment of snoring and sleep apnoea. Presentation at the European Association of Cranio-Maxillo-Facial Surgery in Bologna, Italy, 9.–12.09.2008. *J Craniomaxillofac Surg* 2008;**36**(Suppl. 1):5.
- Lye KW, Waite PD, Meara D, Wang D. Quality of life evaluation of maxillomandibular advancement surgery for treatment of obstructive sleep apnea. *J Oral Maxillofac Surg* 2008;**66**:968–72.
- Abramson ZR, Susarla S, Tagoni JR, Kaban L. Three-dimensional computed tomographic analysis of airway anatomy. *J Oral Maxillofac Surg* 2010;**68**:363–71.
- Longerich UJ, Sailer HF. New method of computed tomography upper airway measurement and new computed tomography positioning technique in patients with sleep apnea. *J Craniomaxillofacial Surg* 1996;**24**(Suppl 1): 143.
- Abramson Z, Susarla S, August M, Troulis M, Kaban L. Three-dimensional computed tomographic analysis of airway anatomy in patients with obstructive sleep apnea. *J Oral Maxillofac Surg* 2010;**68**:354–62.
- Ronchi P, Novelli G, Colombo L, Valsecchi S, Oldani A, Zucconi M, et al. Effectiveness of maxillo-mandibular advancement in obstructive sleep apnea patients with and without skeletal anomalies. *Int J Oral Maxillofac Surg* 2010;**39**:541–7.
- Lee NR, Givens Jr CD, Wilson J, Robins RB. Staged surgical treatment of obstructive sleep apnea syndrome. *J Oral Maxillofac Surg* 1999;**57**:382–5.
- Trauner R, Obwegeser H. The surgical correction of mandibular prognathism and retrognathia with consideration of genioplasty. I. Surgical procedures to correct mandibular prognathism and reshaping of the chin. *Oral Surg Oral Med Oral Pathol* 1957;**10**:677–89.
- Li KK, Guilleminault C, Riley RW, Powell NB. Obstructive sleep apnea and maxillomandibular advancement: an assessment of airway changes using radiographic and nasopharyngoscopic examinations. *J Oral Maxillofac Surg* 2002;**60**:526–30.
- Fairburn SC, Waite PD, Vilos G, Harding SM, Bernreuter W, Cure J, et al. Three-dimensional changes in upper airways of patients with obstructive sleep apnea following maxillomandibular advancement. *J Oral Maxillofac Surg* 2007;**65**:6–12.
- Schendel SA, Powell NB. Surgical orthodontic management of sleep apnea. *J Craniofac Surg* 2007;**18**:902–11.
- Hochban W. Surgical treatment of obstructive sleep apnea. *Otorhinolaryngol Nova* 2000;**10**:149–56.



26. Smatt Y, Ferri J. Retrospective study of 18 patients treated by maxillomandibular advancement with adjunctive procedures for obstructive sleep apnea syndrome. *J Craniofac Surg* 2005;**16**:770–7.
27. Mayer P, Pépin JL, Bettega G, Veale D, Ferretti G, Deschaux C, et al. Relationship between body mass index, age and upper airway measurements in snorers and sleep apnoea patients. *Eur Respir J* 1996;**9**: 1801–9.
28. Li HY, Chen NH, Wang CR, Shu YH, Wang PC. Use of 3-dimensional computed tomography scan to evaluate upper airway patency for patients undergoing sleep disordered breathing surgery. *Otolaryngol Head Neck Surg* 2003;**129**:336–42.

Address:
Max J. Zinser
Department of Craniomaxillofacial and
Plastic Surgery
University Cologne
Kerpener Straße 62
50937 Köln
Germany
Tel: +49 171 8349256;
Fax: +49 221 478 5774
E-mail: drmaxzinser@yahoo.de

Zuse-Institut Berlin (ZIB), Department Visualization & Data Analysis, Research Group ‘Medical Planning’

The Zuse Institute Berlin (ZIB, or Konrad-Zuse-Zentrum für Informationstechnik Berlin) is a research institute for applied mathematics and computer science in Berlin.

The ZIB was founded by law as a statutory establishment and as a non-university research institute of the State of Berlin in 1984. In close interdisciplinary cooperation with the Berlin universities and scientific institutions Zuse Institute implements research and development in the field of information technology with a particular focus on application-oriented algorithmic Mathematics and practical Computer Science. ZIB also provides high-performance computer capacity as an accompanying service.

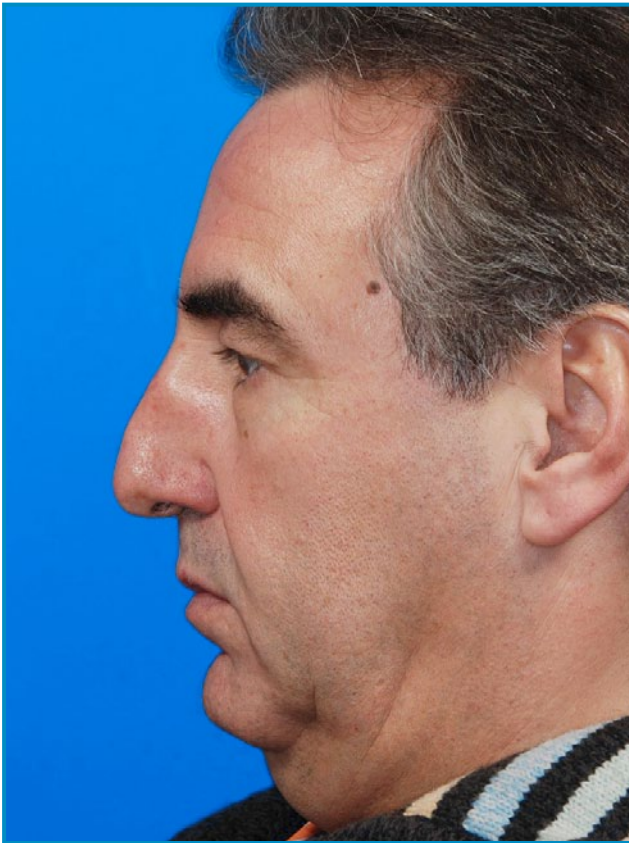Konrad Zuse, born in Berlin in 1910, is the namesake of the ZIB.



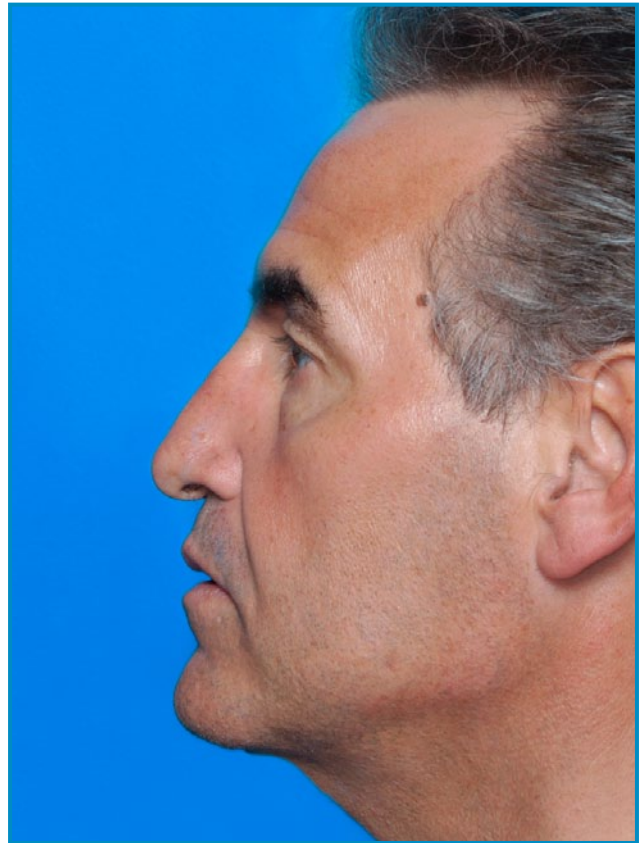


HEALING OF OBSTRUCTIVE SLEEP APNEA LEADS TO MANY LASTING EFFECTS ON PUBLIC HEALTH AND HEALTH ECONOMICS:

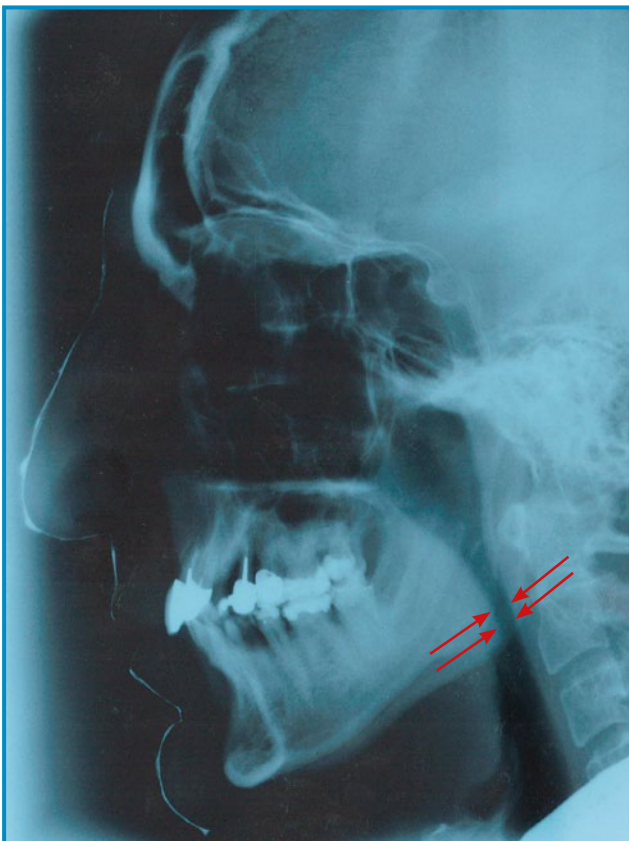1. Prevention of heart attacks
2. Prevention of stroke
3. Loss of weight
4. Less upper airway infections
5. Less absenteeism from work
6. Better physical and intellectual performance
7. Better social integration
8. Better partner relations
9. Better life quality



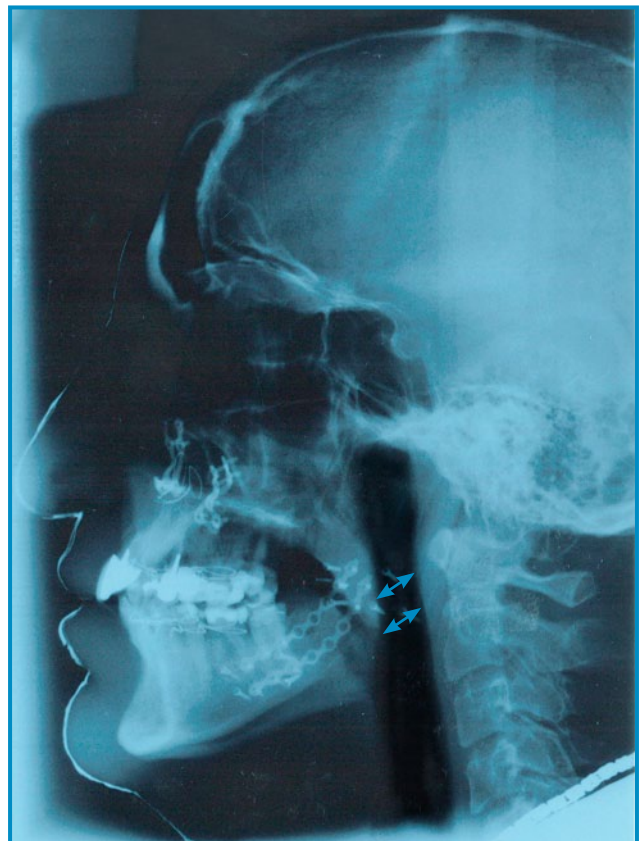before | Sleep apnea patient with typical backward profile of the face, with small chin and double chin.



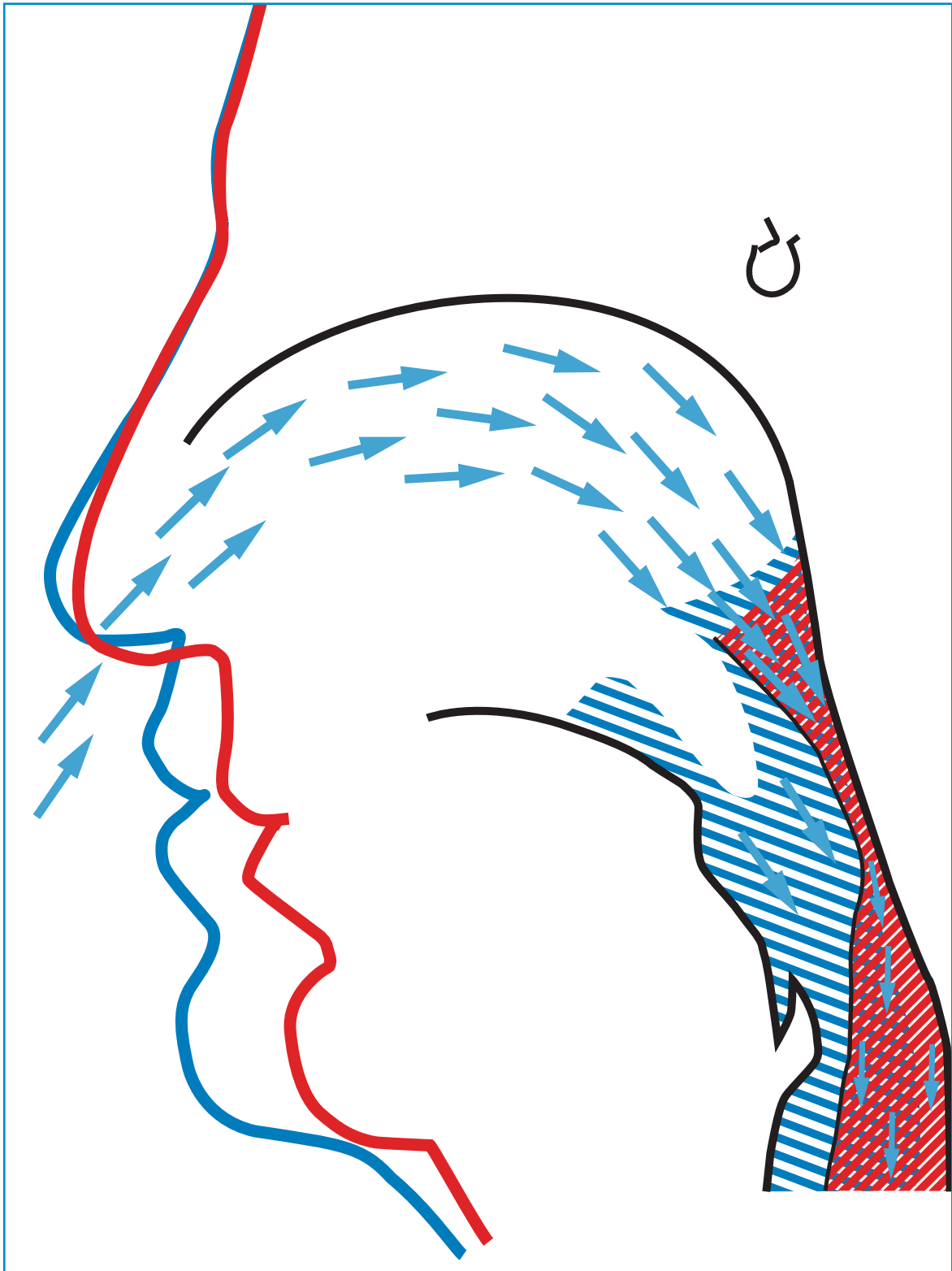
after | The same patient after surgery, with a normal face profile and chin, no double chin, weight loss and wide airways.



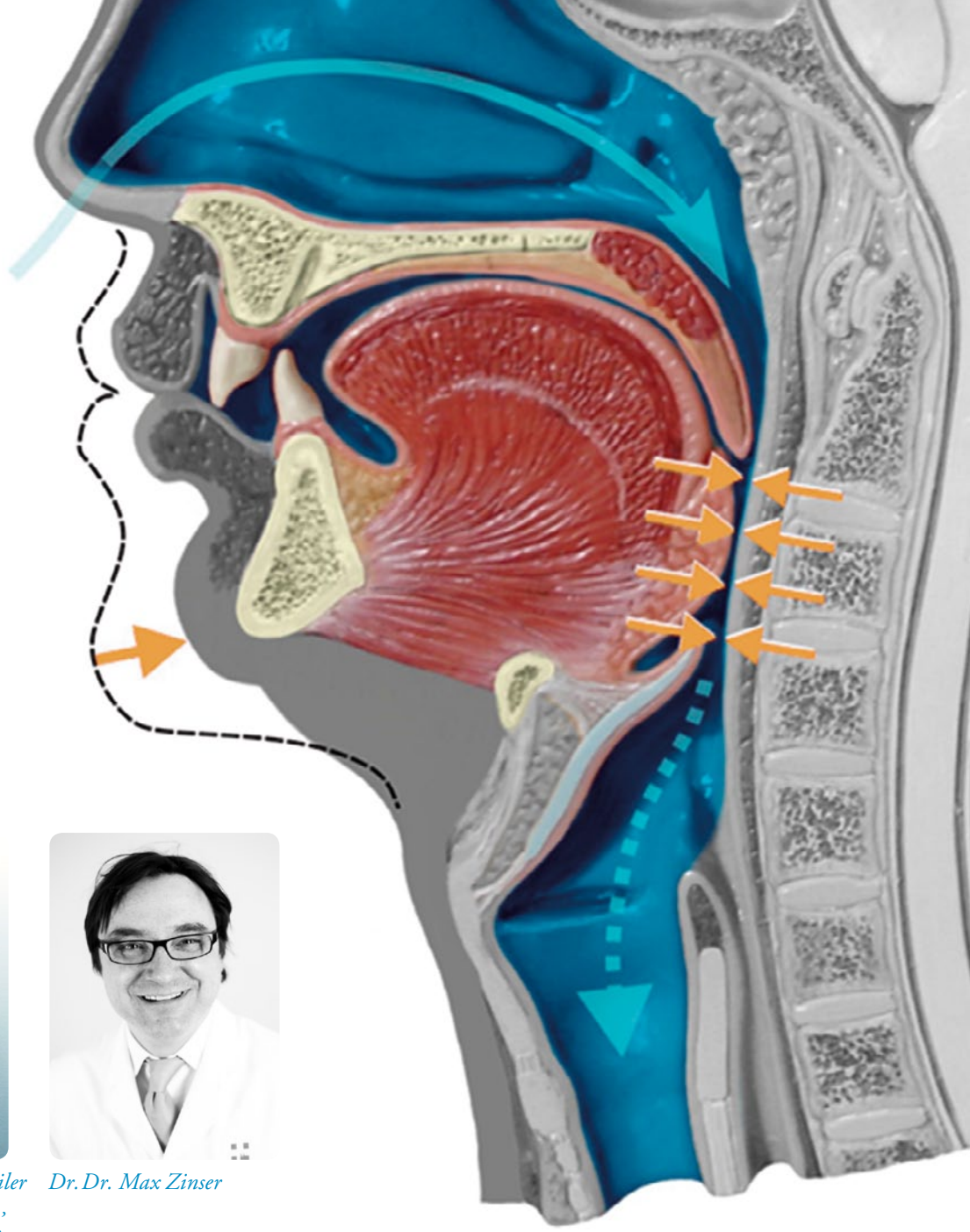
before | Sleep apnea patient with very narrow airways.



after | The same patient after surgery, with now very wide airways.



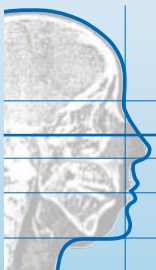
before surgery | narrow airways and small chin
after surgery | wide airways and no more double chin



*Professor Hermann F. Sailer Dr. Dr. Max Zinser
Dr. med., Dr. med. dent.,
Dr. h.c. mult., Dr. sc. h.c.,
FDSRCS (Engl.), FRCS
(Edinb.)*

We are looking forward to consult you!

**For more information, please contact:
Tel. +41 43 268 30 78**



KLINIK PROFESSOR SAILER

Aesthetic Maxillofacial Surgery

Toblerstrasse 51, 8044 Zurich, Switzerland

Tel. +41 43 268 3070, Fax +41 43 268 3071

E-mail: info@sailerclinic.com, www.sailerclinic.com, www.schlafapnoe.com/en

